



Intestinal Dilation Syndrome (IDS)

Other names: Brown Breeder Enteritis (BBE), Idiopathic Eosinophilic Enteritis (IEE)

Etiology

1. Unknown etiology.
2. IDS is mainly associated with White Plymouth Rock (WPR) hens of all genetic lines (usually the female parent stock (PS) of commercial brown laying hens), but is also sporadically found in cage-free commercial brown hens.
3. One hypothesis is that the intestine has been damaged early in the rearing period by coccidia, bacteria, viruses, parasites or allergens.
4. Presence of eosinophilic cells suggests a parasitic or allergic etiology but none have been proven.
5. There is no evidence that Marek's or Lymphoid leukosis are involved in this condition.

Clinical Picture

1. IDS occurs in brown egg PS (not in males or white egg parents on the same farm).
2. Clinical disease occurs predominantly during the laying period. The first occurrence on a farm tends to occur during the mid-laying period with peak incidence between 39 and 45 weeks of age. There is a high risk of repeat outbreaks on a farm. Subsequent outbreaks occur in younger flocks and with increased severity.
3. The condition is associated more with rearing houses using deep litter, where exposure to feces and litter components is greater. There has been no difference in occurrence associated with litter type (wood shavings versus rice hulls).
4. Affected hens develop pale combs, become unthrifty, lose body condition, and fall out of egg production. Some mortality occurs, but most of the loss is due to culling of hens that have gone out of production. Flock feed consumption and egg production gradually decline as more hens are affected.
5. Mortality or culling of poor performing females continues at a rate of 0.2–0.5% per week. Cumulative flock depletion can reach 10–20%.
6. **All brown parent varieties are susceptible.** IDS has been reported in many commercial varieties. IDS has not been reported in Brown (WPR) GP or white egg breeders. In Silver Brown, IDS occurs in the commercial layer but not in PS.

Post-Mortem Findings

1. Segmented dilation (ballooning) of the small intestine 10–20 cm (4–8 in) in length, often located in the area of the junction of the ileum and jejunum (Meckel's diverticulum).
2. IDS affected hens generally have shorter intestinal tracts compared to unaffected birds (approximately 1/3 reduction of normal length).
3. Intestinal wall appears thickened and pale in color. The intestinal mucosa appears uneven, giving a bumpy appearance. Mesenteric vessels can appear prominently on the serosa.
4. In more chronic cases, torsion or intussusception of the intestine occurs.



Figure 1. An affected hen (left) has reduced feed consumption, will lose body weight and go out of egg production. Loss of hatching eggs is a major economic loss in affected flocks. Image: G. Zavala.

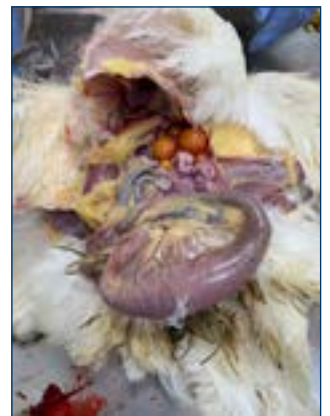

Figure 2. IDS is characterized by segmental dilatation of the small intestine. Image: G. Zavala.

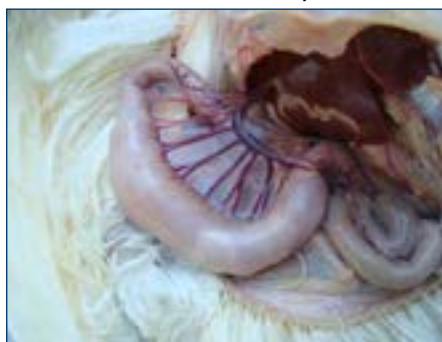

Figure 3. The dilatation typically occurs at the junction of the jejunum and ileum. Image: G. Zavala.

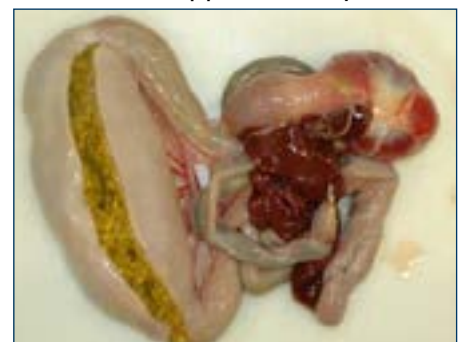

Figure 4. Affected intestinal wall is thickened. Image: G. Zavala.

Fact Sheet – Intestinal Dilation Syndrome (IDS)

Histopathology

1. Segmental chronic granulocytic (lymphocytes and eosinophils) enteritis with villous atrophy, expansion of the lamina propria with edema and granulocytes, loss of crypts with hyperplasia of remaining crypts. Myositis in some segments beneath the areas of granulocytic enteritis. Fibromuscular dystrophy of mesenteric arteries.

Treatments

1. Improving the cleanliness of the breeder house and particularly the rearing environment. Reduce exposure of birds to feces and litter. Optimize growth and development of the gastrointestinal tract (0–6 weeks).
2. Placing rearing flocks on slats or wire has been shown to reduce the incidence of IDS outbreaks and lead to a gradual reduction of occurrence on affected farms. Changing to slats has not eliminated IDS in every case.
3. Practice an effective coccidia control program in the flock either by vaccination or preventive medication.
4. Many treatments have been attempted with variable success. Antibiotic treatments, prebiotic, probiotic, antiparasitic treatments, feed acidification and dietary modifications have not consistently improved the condition.

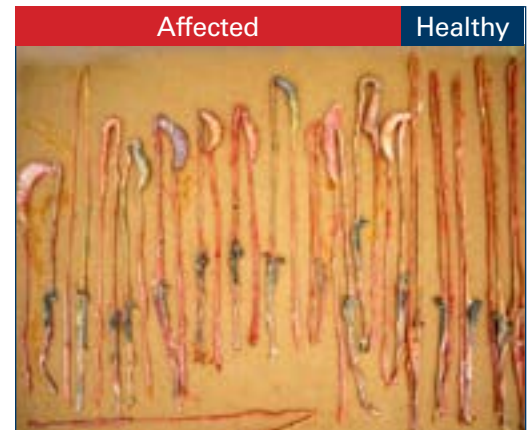


Figure 5. Intestinal length is shorter in affected hens compared to healthy hens. Image: G. Zavala.

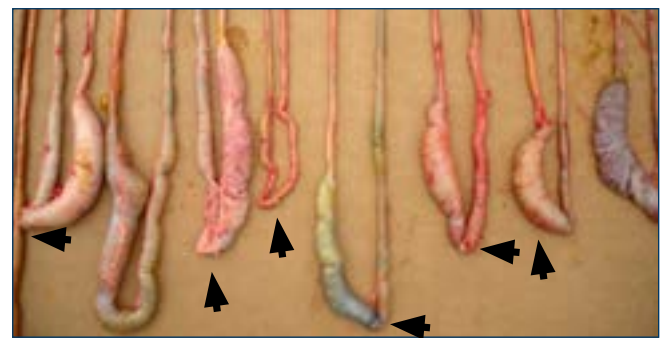


Figure 6. Segmental intestinal dilations shown. Arrows indicate the location of Meckel's diverticulum. Image: G. Zavala.

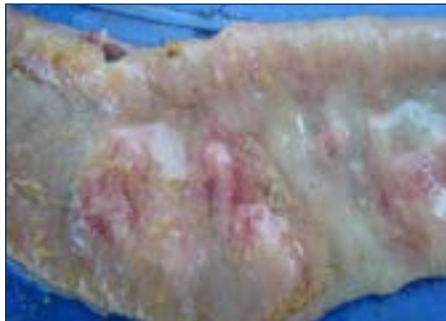


Figure 7. Intestinal mucosa has an uneven appearance. Image: G. Zavala.

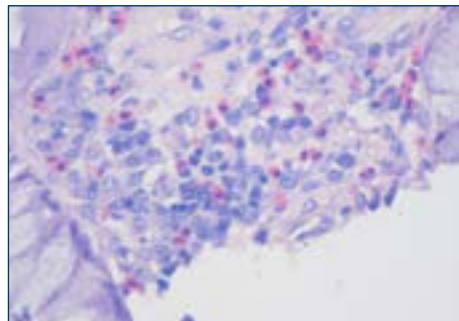


Figure 8. Inflammatory cells are lymphocytes and probably eosinophils (pink stained cells).

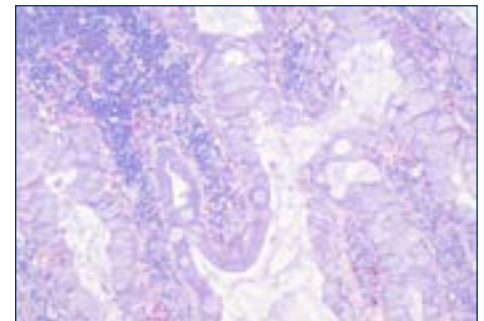


Figure 9. Villi are distorted, fused, and clubbed in appearance. There is a loss of crypts and hyperplasia in the remaining crypts. Enlargement of enterocytes with mucus.

For More Information



[CLINICAL PRESENTATION AND PATHOLOGY OF INTESTINAL DILATATION SYNDROME \(IDS\) IN BROWN LAYERS](#) (G.Zavala, S.M.Williams, F. Hoerr, D.W.Trampel, AAAP/AVMA Meeting 2013, Chicago, Illinois)

